

Intravitreal Moxifloxacin: Retinal Safety Study with Electroretinography and Histopathology in Animal Models

Hua Gao,¹ Mark E. Pennesi,² Xiaoxi Qiao,¹ Mohan N. Iyer,² Samuel M. Wu,² Eric R. Holz,² and William F. Mieler³

PURPOSE. To determine whether moxifloxacin can be used safely as an intraocular antibiotic, retinal safety of intravitreal moxifloxacin was studied with electroretinography (ERG) and histopathology in animal models.

METHODS. Moxifloxacin was injected into mouse eyes at intravitreal concentrations of 5 to 500 $\mu\text{g}/\text{mL}$ and into rabbit eyes at 150 $\mu\text{g}/\text{mL}$. As the control, the vehicle was injected into the fellow eyes of each animal. Four weeks after injection, ERG recordings were performed, and animal eyes were processed for histologic examination.

RESULTS. ERG studies showed no significant difference between control and moxifloxacin-injected eyes at any dose in either the mouse or rabbit model. Histologic examination revealed no retinal abnormality in mice at 5 to 100 $\mu\text{g}/\text{mL}$ or in rabbits at 150 $\mu\text{g}/\text{mL}$ intravitreal moxifloxacin. In mice at 500 $\mu\text{g}/\text{mL}$, occasional focal retinal necroses were observed, suggesting isolated retinal toxicity at this concentration of moxifloxacin.

CONCLUSIONS. Intravitreal moxifloxacin, up to 100 $\mu\text{g}/\text{mL}$ in mice or 150 $\mu\text{g}/\text{mL}$ in rabbits, caused no ERG or retinal histologic abnormality. These results indicate that moxifloxacin is a safe intravitreal antibiotic in mouse and rabbit animal models. If proven safe and efficacious by further study in humans, intravitreal injection of moxifloxacin could be considered as an alternative to currently used antibiotics in selected patients with resistance or allergy to the more traditional antibiotics. (*Invest Ophthalmol Vis Sci.* 2006;47:1606-1611) DOI: 10.1167/iovs.05-0702

Bacterial endophthalmitis is a devastating ocular disease that can lead to permanent blindness in a short time if not treated properly and promptly. The Endophthalmitis Vitrectomy Study (EVS) showed that after intraocular surgery such as cataract extraction, 94% of culture-proven incidences of endophthalmitis were due to Gram-positive bacteria, and only approximately 6% were due to Gram-negative bacteria.¹ The treatment recommendations from the EVS for endophthalmitis

are vancomycin for Gram-positive bacteria and amikacin or tobramycin for Gram-negative bacteria.² Today, most cases of endophthalmitis are treated with vancomycin and ceftazidime, because amikacin and tobramycin have been reported to cause retinal infarction, even at therapeutic concentrations.³ It would be much more beneficial for the patients and more convenient for ophthalmologists if only one antibiotic instead of two could be used to treat both Gram-positive and Gram-negative bacterial endophthalmitis.

Fluoroquinolone has been widely used in ophthalmology, because of its broad Gram-positive and Gram-negative coverage.⁴⁻⁷ However, significant bacterial resistance to second- and third-generation fluoroquinolone emerged in the mid-1990s. For example, resistant strains causing bacterial keratitis increase from 5% to 35% over a period of 4 years.^{8,9} The in vitro susceptibility rates of *Staphylococcus aureus*, isolated from patients with endophthalmitis, to ciprofloxacin, ofloxacin, and levofloxacin decreased from 100% in 1993 to 0% in 2001.¹⁰

Moxifloxacin (Avelox; Bayer Pharmaceuticals Corp., West Haven, CT), a fourth-generation fluoroquinolone, was initially developed to treat Gram-positive bacterial respiratory infections.¹¹⁻¹⁴ Unlike the second- and third-generation fluoroquinolones, which bind to only one of the two key enzymes involved in bacterial DNA replication, moxifloxacin binds both enzymes: bacterial DNA gyrase and topoisomerase IV.^{15,16} More extensive binding provides more effective bacterial killing and less bacterial mutation into resistant organisms. Thus, moxifloxacin provides superior coverage against those Gram-positive bacteria that were already resistant to the second- and third-generation fluoroquinolones, and it also maintains excellent coverage for Gram-negative bacteria.¹⁷ It has been demonstrated that moxifloxacin's minimum inhibitory concentration (MIC) and MIC₉₀ (the concentration of drug causing a 90% growth inhibition of organisms) are the lowest among all generations of fluoroquinolones, and its antibacterial activity is the highest against the most common Gram-positive pathogens in the EVS, such as coagulase negative *Staphylococcus*, *S. aureus*, and *Streptococcus pneumoniae*.¹

This experimental study was designed to examine whether moxifloxacin can be safely used as an intravitreal agent in the treatment of bacterial endophthalmitis in animal models. Intravitreal injection of moxifloxacin was performed on mice and rabbits, and retinal function and morphology were subsequently examined using electroretinography (ERG) and histology studies.

MATERIALS AND METHODS

Animals

C57BL/6J mice 4 weeks of age (~25 g) were obtained from the Charles River Laboratories (Wilmington, MA). Mice were fed ad libitum with laboratory chow (Purina, Richmond, IN) and water. Dutch Belted rabbits weighing 2 to 2.5 kg were obtained from the Myrtle's Rabbitry, Inc. (Thompson Station, TN). The animals were housed in room light-

From the ¹Department of Ophthalmology, Indiana University School of Medicine, Indianapolis, Indiana; the ²Department of Ophthalmology, Baylor College of Medicine, Houston, Texas; and the ³Department of Ophthalmology and Visual Science, University of Chicago, Chicago, Illinois.

Supported by the Bayer Pharmaceutical Company and Research to Prevent Blindness.

Submitted for publication June 6; revised September 2 and December 13, 2005; accepted February 10, 2006.

Disclosure: H. Gao, None; M.E. Pennesi, None; X. Qiao, None; M.N. Iyer, None; S.M. Wu, None; E.R. Holz, None; W.F. Mieler, None

The publication costs of this article were defrayed in part by page charge payment. This article must therefore be marked "advertisement" in accordance with 18 U.S.C. §1734 solely to indicate this fact.

Corresponding author: Hua Gao, Department of Ophthalmology, Indiana University School of Medicine, 702 Rotary Circle, Indianapolis, IN 46202; hgao@iupui.edu.

ing with a 12-hour light–dark cycle. The experiments were performed in accordance with the ARVO Statement for the Use of Animals in Ophthalmic and Vision Research, and the protocol was approved by the Institutional Review Board of Baylor College of Medicine.

Intravitreal Injection

Mice were anesthetized by intraperitoneal injection of a solution containing ketamine (95 mg/mL) and xylazine (5 mg/mL) at a dose of 0.2 mL/100 g body weight. Proparacaine hydrochloride 0.5% (Alcon Laboratories, Inc., Fort Worth, TX) was used for additional topical anesthesia. Ofloxacin ophthalmic solution 0.3% (Allergan Inc, Irvine, CA) was applied to the ocular surface before injection, and bacitracin ophthalmic ointment (E. Fougera & Co., Melville, NY) was applied after injection, to prevent infection. Moxifloxacin, a white lyophilized powder, was kindly provided by the Bayer Pharmaceuticals Corp. (West Haven, CT). The minimum inhibitory concentration (MIC) of moxifloxacin to bacterial keratitis isolates was found to be 0.016 to 4.0 $\mu\text{g/mL}$.¹⁸ Because this is a retinal toxicity study, we chose to use 5 $\mu\text{g/mL}$ as a baseline concentration. Moxifloxacin solutions were serially diluted with sterile water as instructed by the manufacturer so that the final intravitreal concentrations were 5, 25, 50, 100, and 500 $\mu\text{g/mL}$ based on an estimated adult mouse vitreous volume of 20 μL .¹⁹ Serially diluted moxifloxacin solutions of 2 μL were injected intravitreally into mouse eyes under a dissecting microscope using a microinjector (Hamilton Co., Reno, NV). Five mice were used for each concentration. A 30-gauge needle was first used to make a punch incision 0.5 mm posterior to the temporal limbus, and the microinjector needle was then inserted through the incision, approximately 1.5 mm deep, angled toward the optic nerve until the tip of needle was visualized in the center of the vitreous. Sterile water of the same volume (2 μL) was injected into the fellow eyes of each mouse as the control. After injection, animals were kept in ambient light on a 12-hour light–dark schedule. Four weeks after injection, animals were processed for electroretinogram (ERG) recordings and subsequent retinal histology examinations.

Dutch Belted rabbits were also used, to examine the interspecies difference and to confirm the experimental results in the mice. The rabbits were anesthetized with an intramuscular injection of 0.5 mL/kg body weight of a solution containing ketamine 42.8 mg, xylazine 8.6 mg, and acepromazine 1.4 mg/mL. Topical proparacaine hydrochloride was used for additional anesthesia, and ofloxacin and bacitracin were also used to prevent infection. After anterior chamber paracentesis, 200 μg moxifloxacin in a volume of 0.1 mL was injected intravitreally into the left eye of each rabbit. The injection was performed with a 27-gauge needle through a site 2 mm posterior to the superior limbus. A previous report showed that rabbit vitreous volume was 1.5 mL,²⁰ but we measured vitreous volume in 27 adult rabbits and found it to be 1.2 mL. Based on this measurement, the final intravitreal concentration of moxifloxacin was approximately 150 $\mu\text{g/mL}$, with the concentration confirmed by HPLC (high pressure liquid chromatography). Five rabbits were used. The fellow eye of each rabbit was injected with 0.1 mL drug vehicle (water) as the control. After the injection, the animals were kept for 4 weeks in ambient light on a 12-hour light/dark schedule. The rabbits were examined with indirect ophthalmoscopy, and no retinal changes or detachments were noted in any eye 4 weeks after the injections. ERGs were then performed with subsequent retinal histology examinations.

ERG Recordings

The mice were placed in dark adaptation overnight before ERG testing. In dim red light, mice were anesthetized with a solution of ketamine and xylazine, as described earlier. Pupils were dilated with a single drop of 0.5% tropicamide and 2.5% phenylephrine. A drop of 0.5% proparacaine hydrochloride was applied for corneal anesthesia. The mice were placed on a heating pad maintained at 39°C, inside a Ganzfeld dome coated with highly reflective white paint (Munsell Paint, New Windsor, NY). A small amount of 2.5% methylcellulose gel

was applied to the eye, and a platinum electrode was placed in contact with the center of the cornea. Similar platinum reference and ground electrodes were placed in the forehead and tail, respectively. After placement in the dome, the mice were allowed to remain in complete darkness for 5 minutes before the ERG was started. Signals were amplified (P122 band-pass 0.1–1000 Hz; Grass-Telefactor, West Warwick, RI). Data were then acquired at a sampling rate of 10,000 Hz (DAQ board; National Instruments Laboratory; Austin, TX). Traces were averaged and analyzed with custom software (written in MatLab; The MathWorks, Natick, MA).

For ERGs in the rabbits, the test protocol was similar to that in the mice. The rabbits were dark adapted for 1 hour, and 1 drop of 1% tropicamide and 2.5% phenylephrine were instilled in the left eyes for dilation. After 1 drop of hydroxypropyl methylcellulose (Goniosol; Chiron Vision Ophthalmics) was instilled in the eye, a corneal contact electrode (a contact electrode with gold foil; JET; LKC Technologies, Gaithersburg, MD) was placed on the cornea. The reference electrode was placed near the lid, and the ground electrode, in the scruff of the neck. The ERG signals were amplified, and data were acquired as in the mouse ERG test. Before intravitreal moxifloxacin injection, ERG was performed as a baseline. Four weeks after the injection, ERG was repeated on the same eyes.

Flashes were calibrated in a manner similar to that described previously²¹ and are described in detail elsewhere.²² Flashes for scotopic measurements were generated by a photostimulator (model PS-33+; Grass-Telefactor). Light was spectrally filtered with a 500-nm interference filter (Edmund Industrial Optics, Barrington, NJ). A series of metal plates with holes of various diameters and glass neutral-density filters were used to attenuate the flash. Flashes varied in intensity from -3.85 to -0.76 log scotopic $\text{cd}\cdot\text{s}/\text{m}^2$. The scotopic b-wave was digitally filtered using the “filtfilt” function in the software (low pass filter, $F_c = 60$ Hz; MatLab; The MathWorks), to remove oscillatory potentials before fitting. The relationship between b-wave amplitude and flash intensity can be described by a saturating hyperbolic function (Naka-Rushton) with the formula:

$$b = \frac{b_{\text{max,scot}} \cdot I}{b_{\text{max,scot}} + I_{0.5}}$$

where $b_{\text{max,scot}}$ is the saturated scotopic b-wave amplitude, and $I_{0.5}$ is the intensity that provides half saturation. The baseline and peak of each filtered trace was measured, and the data for multiple intensities were fit to the equation.

For analysis of the a-wave and cone function, 1500-watt xenon flash lamps (Novatron, Dallas, TX) were used to provide intense illumination, approximately 2.92 log scotopic $\text{cd}\cdot\text{s}/\text{m}^2$. To analyze the rod function, we used the following equation (Lamb-Pugh model) to fit a series of a-waves at increasing intensities:

$$1 - \frac{a(t)}{a_{\text{max}}} = \exp\left[-\frac{1}{2} \cdot \phi \cdot A \cdot (t - t_{\text{eff}})^2\right]$$

where $a(t)$ is the a-wave, a_{max} is its saturating amplitude, ϕ is the number of photoisomerizations rod produced by the flash, A is the amplification factor, and t_{eff} is a brief delay. Cone-driven responses were recorded in the presence of a 540-nm rod-saturation background light that measured 40 scotopic cd/m^2 in intensity. The oscillatory potentials were removed before measurement by digitally filtering the cone driven b-wave with the filtfilt function in MatLab (low pass filter, $F_c = 30$ Hz). After removal of the oscillatory potentials, the peaks of the b-wave ($b_{\text{max,phot}}$) and a-wave ($a_{\text{max,phot}}$) were measured.

Retinal Histology

After ERG tests, mice were euthanatized with an overdose of intraperitoneal ketamine and xylazine, and rabbits were killed with a lethal cardiac injection of Beuthanasia-D (Schering Plough Animal Health, Omaha, NE). The animal eyes were then enucleated, a large full-

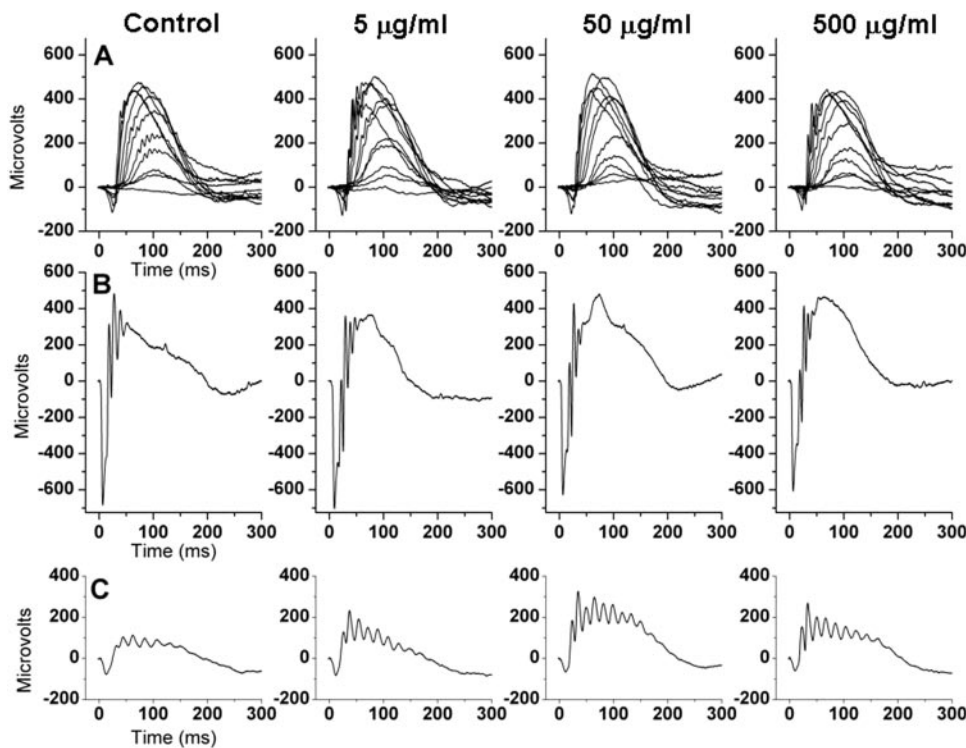


FIGURE 1. ERG recordings from mouse eyes injected with various concentrations of intravitreal moxifloxacin (5, 50, and 500 $\mu\text{g}/\text{mL}$) or drug vehicle as the control. (A) Scotopic recordings demonstrated a progressive increase in b-wave amplitude with increasing intensity of light. b-Waves measured from the control eyes and moxifloxacin-injected eyes showed very similar morphology and amplitude. (B) ERG response to an intense flash that saturates the rod photoreceptors. The saturated scotopic a-waves from control eyes and moxifloxacin-injected eyes show no significant difference. To measure cone function, photopic ERG was recorded in the presence of a rod-saturation background (C). Again, there was no significant difference in the photopic responses measured from control eyes and moxifloxacin-injected eyes (see Table 1 for detailed data).

thickness incision was made in the cornea, and the eye was fixed immediately in 4% formaldehyde in 0.1 M phosphate buffer (pH 7.4). After 15 minutes in the fixative, the lens was removed and the eye was cut along the cornea-optic nerve axis into halves. Gross examinations of the tissues were performed. Tissues were further fixed overnight in 4% paraformaldehyde and 0.5% glutaraldehyde in 0.1 M phosphate buffer (pH 7.4). Tissues were then embedded in paraffin, sectioned at a thickness of 6 μm , and stained with hematoxylin and eosin. A light microscope was used for histologic examinations.

RESULTS

Electroretinograms

ERG recordings from control and moxifloxacin-injected mouse eyes are shown in Figure 1. Figure 1A shows scotopic b-wave responses to increasing intensities of flashed light. The scotopic b-wave is a measurement of the extracellular field potential that primarily arises from rod bipolar cells in response to dim flashes of light.²³ The relationship between scotopic b-wave amplitude and intensity can be modeled with a hyperbolic saturation (Naka-Rushton) function. This model yields two parameters, $b_{\text{max,scot}}$ and $I_{0.5}$, representing the maximum b-wave amplitude and the intensity that provides half

saturation, respectively. As shown in Figure 1A, scotopic recordings from control eyes demonstrated a progressive increase in b-wave amplitude with increasing intensity of light. The maximum b-wave amplitude in control eyes was $530 \pm 55 \mu\text{V}$ and the half-saturation intensity measured $1.9 \pm 0.2 \phi/\text{rod}$. The b-waves measured from eyes injected with various concentrations of moxifloxacin demonstrate similar morphology and amplitude. There was no statistically significant difference in $b_{\text{max,scot}}$ or $I_{0.5}$ between control eyes and any of the groups of moxifloxacin-injected eyes (Table 1). Significance was measured with both the Student's *t*-test (two-tailed, assuming equal variance) and ANOVA. Figure 1B shows the ERG response to an intense flash that saturates the rod photoreceptors. The saturated scotopic a-wave from control eyes measured $690 \pm 25 \mu\text{V}$. Once again, there was no significant difference between control eyes and those injected with moxifloxacin (Table 1). To determine cone function, photopic ERGs were measured in the presence of a rod-saturation background (Fig. 1C). For control eyes, $b_{\text{max,phot}}$ measured $190 \pm 40 \mu\text{V}$ and $a_{\text{max,phot}}$ measured $75 \pm 15 \mu\text{V}$. Again, there was no significant difference in the photopic response measured from control eyes and moxifloxacin-injected eyes (Table 1).

TABLE 1. ERG Data of Mouse Eyes with Various Intravitreal Concentrations of Moxifloxacin

Dose	$b_{\text{max,scot}}$ (μV)	$I_{0.5}$ (ϕ/rod)	$a_{\text{max,scot}}$ (μV)	$b_{\text{max,phot}}$ (μV)	$a_{\text{max,phot}}$ (μV)
Control ($n = 4$)	530 ± 55	1.9 ± 0.2	690 ± 25	190 ± 40 ($n = 3$)	75 ± 15
5 $\mu\text{g}/\text{mL}$ ($n = 4$)	430 ± 30	1.8 ± 0.1	550 ± 45	230 ± 10 ($n = 4$)	65 ± 10
50 $\mu\text{g}/\text{mL}$ ($n = 4$)	575 ± 35	2.6 ± 0.4	590 ± 20	210 ± 50 ($n = 3$)	50 ± 10
500 $\mu\text{g}/\text{mL}$ ($n = 5$)	505 ± 25	2.0 ± 0.01	630 ± 35	270 ± 25 ($n = 5$)	55 ± 10

Concentration is the intravitreal concentration of moxifloxacin. Control is the eyes injected with the drug vehicle, which was water. $b_{\text{max,scot}}$ is the maximum b-wave amplitude in scotopic condition, $I_{0.5}$ is the flash intensity that provides half saturation, and $a_{\text{max,scot}}$ is the maximum a-wave amplitude. $b_{\text{max,phot}}$ and $a_{\text{max,phot}}$ are the maximum b-wave amplitude and maximum a-wave amplitude, respectively, in photopic stimulation.

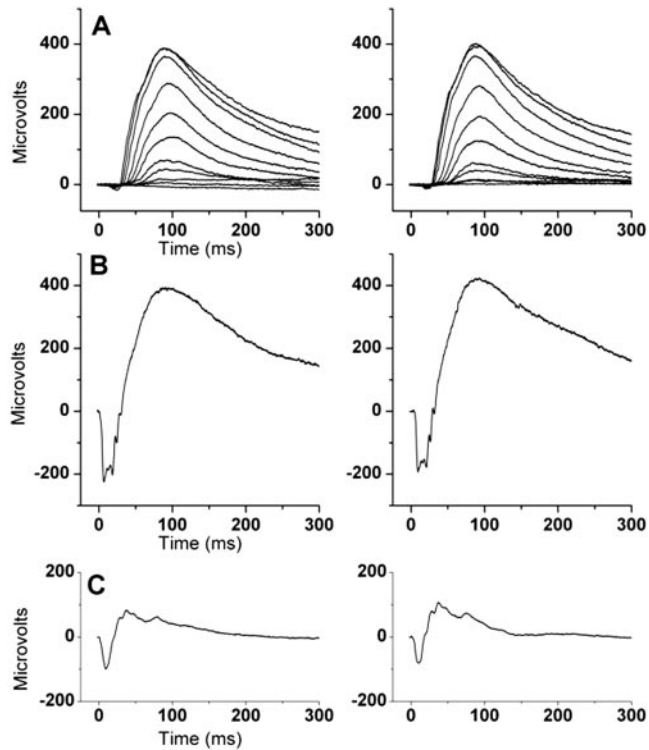


FIGURE 2. ERG recordings from rabbit eyes before (*left*) and 4 weeks after (*right*) moxifloxacin injection. (A) Scotopic b-wave responses to increasing intensities of flashed light and (B) saturated scotopic a-wave and (C) photopic recordings. Statistical analysis shows no significant difference between pre- and postinjection groups in any of these either scotopic or photopic recordings.

Similarly, ERG recordings were performed in rabbit eyes before and 4 weeks after moxifloxacin injection. Scotopic b-wave responses to increasing intensities of flashed light (Fig. 2A), saturated scotopic a-wave (Fig. 2B), and photopic recordings (Fig. 2C) were measured before (left) and after (right) moxifloxacin injection. Scotopic b_{\max} was 397 ± 54 and $408 \pm 23 \mu\text{V}$, and $I_{0.5}$ was 9.4 ± 0.6 and $9.1 \pm 0.7 \phi/\text{rod}$, before and after moxifloxacin injection, respectively. Scotopic a_{\max} was 199 ± 17 and $177 \pm 54 \mu\text{V}$; photopic b_{\max} was 192 ± 12 and $177 \pm 13 \mu\text{V}$, and photopic a_{\max} was -94 ± 5 and $-85 \pm 3 \mu\text{V}$, before and after moxifloxacin injection, respectively. Again, statistical analysis showed no significant difference between the pre- and postinjection groups in any of the scotopic or photopic recordings (Fig. 2). Thus, ERG studies show no evidence of retinal functional change in either the mouse or rabbit model after intravitreal moxifloxacin injection of any concentration groups tested in this study.

Retinal Histology

Gross examination of eye specimens showed no evidence of retinal detachment, retinal hemorrhages, or signs of infection in any moxifloxacin injected or control eyes in either mice or rabbits. Two mouse lenses were found to be opacified after intravitreal injection, probably due to needle injury, and these two eyes were excluded from the study. Four rabbit lenses were noted to have focal peripheral opacities after intravitreal injection. These eyes were included in the study, since the lens opacity was small and located in the periphery, and the ERG data from these eyes were in the range of the other eyes without lens injury. A small vitreous hemorrhage was noted in the inferior periphery of one rabbit eye, but no retinal detachment or retinal hemorrhage was detected. This eye was also

included in the study, since the ERG data were in the range of data in the other eyes.

Histologic examination with light microscopy did not reveal any retinal abnormality in the mouse or rabbit control eyes injected with drug vehicle (images not shown). In the mouse eyes with intravitreal moxifloxacin from 5.0 to 100 $\mu\text{g}/\text{mL}$, no retinal abnormality was observed in any retinal area (Fig. 3A). In the mouse eyes with 500 $\mu\text{g}/\text{mL}$ intravitreal moxifloxacin, very small focal retinal necroses were occasionally noted in the retina (Fig. 3B). In these necrotic areas, the photoreceptor layer was disorganized. Photoreceptor degeneration was evident, and photoreceptor inner and outer segments were absent. The inner nuclear layer also showed a mild degenerative change. The ganglion cell layer appeared intact. In the areas where focal necrosis was not observed, the retina was normal in light microscopy examination. In the rabbit eyes with 150 $\mu\text{g}/\text{mL}$ intravitreal moxifloxacin, histologic examination showed completely normal retinas with no evidence of retina necrosis in any area (Fig. 4).

DISCUSSION

This study shows that moxifloxacin did not display retinal toxicity when examined by ERG or histology, when the intra-

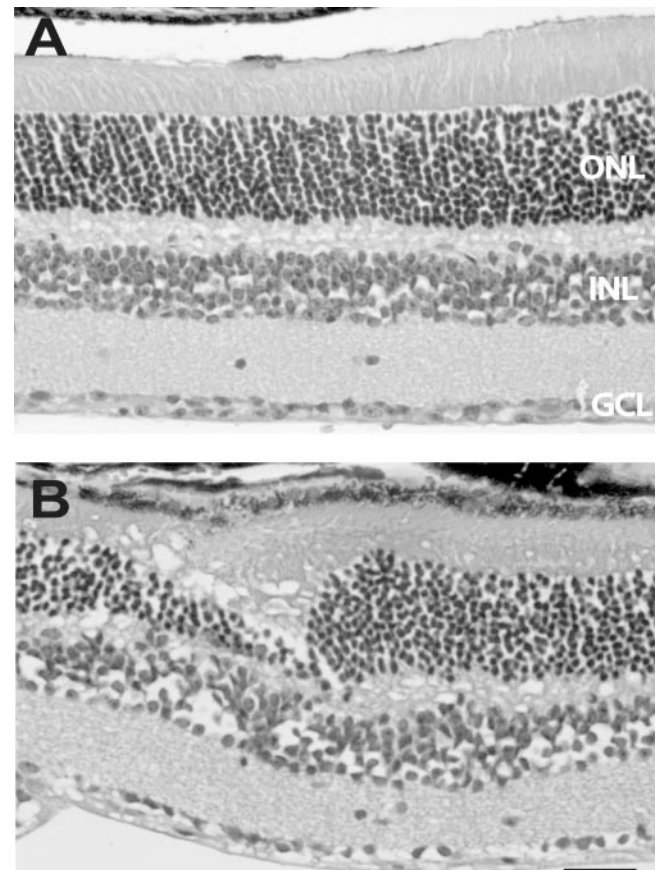


FIGURE 3. Retinal histology of mouse eyes with intravitreal injection of moxifloxacin. (A) In the mouse eyes with intravitreal moxifloxacin from 5.0 to 100 $\mu\text{g}/\text{mL}$, no retinal abnormality was observed in any retinal area. The retinal detachment is an artifact of tissue processing. (B) In the eyes injected with 500 $\mu\text{g}/\text{mL}$ intravitreal moxifloxacin, very small focal retinal necroses were occasionally noted in the retina. In these necrotic areas, the photoreceptor layer was disorganized. Photoreceptor degeneration was evident, and the inner and outer segments were absent. The inner nuclear layer also showed mild degenerative change. ONL, outer nuclear layer; INL, inner nuclear layer; GCL, ganglion cell layer. Scale bar, 100 μm .

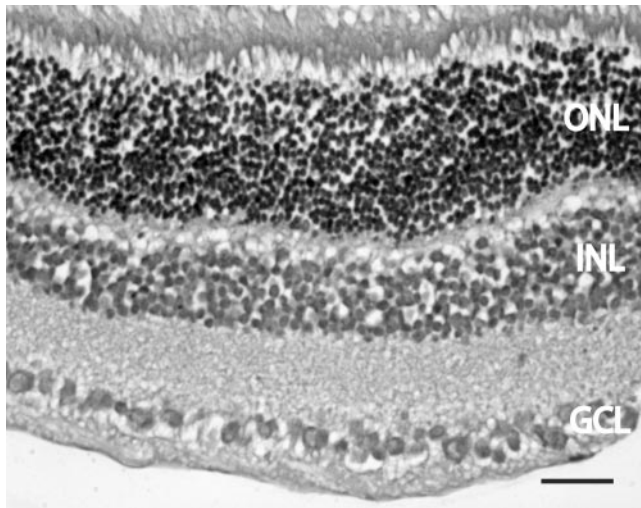


FIGURE 4. Retinal histology of rabbit eyes injected with 150 µg/mL intravitreal moxifloxacin. Histologic examination showed a completely normal retina, with no evidence of retina necrosis in any area. Abbreviations as in Figure 3. Scale bar, 100 µm.

vitreal concentration was 100 µg/mL or less in the mice or 150 µg/mL in the rabbits. When the concentration reached 500 µg/mL in the mice, very slight focal retinal necrosis was occasionally noted on histologic examination, but ERG was not affected. This finding is to be expected, as ERG is a mass electrical response from the entire retina, and focal necrosis would not be expected to cause ERG abnormality. The possible species difference was reduced to a minimum, since two species were examined in our study and revealed very similar intravitreal moxifloxacin levels without retinal toxicity. When these results are extrapolated to humans, moxifloxacin of 400 to 500 µg may be safely injected intravitreally in the eyes without causing ERG or histologic abnormalities, based on the fact that average human vitreous volume is 4 mL. However, further study in human eyes is needed to determine the safe intravitreal moxifloxacin dosage.

Hariprasad et al.²⁴ studied intraocular penetration of topical 0.5% moxifloxacin ophthalmic agent (Vigamox; Alcon Laboratories, Inc.) in 20 patients. They found that the average moxifloxacin aqueous and vitreous concentrations were 2.28 and 0.11 µg/mL, respectively, if the eye drops were given every 2 hours for 3 days, and were 0.88 and 0.06 µg/mL, respectively, if given every 6 hours. Although MIC₉₀ was exceeded in the aqueous for a wide spectrum of pathogens, intravitreal concentration of moxifloxacin was too low for many organisms.²⁴ We also studied intraocular penetration of systemic moxifloxacin in 15 patients.²⁵ The average intravitreal and intracameral moxifloxacin concentrations were 1.34 ± 0.66 and 1.58 ± 0.80 µg/mL, respectively. Compared with topical moxifloxacin, oral moxifloxacin results in a 10-times higher intravitreal concentration. MIC₉₀ levels were achieved in the vitreous and aqueous against a wide spectrum of pathogens, such as *S. epidermidis*, *S. aureus*, *S. pneumoniae*, *S. pyogenes*, *Propionibacterium acnes*, *Haemophilus influenzae*, and *Bacillus cereus*, the most common endophthalmitis-causing organisms. However, the intravitreal or intracameral level achieved by oral moxifloxacin in this study does not exceed the MICs of fluoroquinolone-resistant strains, especially coagulase negative *Staphylococcus* and *S. aureus*, the most common organisms causing endophthalmitis.

As described in the introduction, bacterial resistance to prior-generation fluoroquinolones has increased significantly since the mid-1990s.^{8-10,26} Based on a study of 93 bacterial

endophthalmitis isolates, mean moxifloxacin MICs for fluoroquinolone-susceptible coagulase negative *Staphylococcus* and *S. aureus* were only 0.05 and 0.06 µg/mL, but they were 2.5 µg/mL and 1.75 µg/mL, respectively, for fluoroquinolone-resistant coagulase negative *Staphylococcus* and *S. aureus*.²⁷ In another study of 177 bacterial keratitis isolates, moxifloxacin's MIC₉₀ was as high as 3.0 and 4.0 µg/mL for fluoroquinolone-resistant coagulase negative *Staphylococcus* and *S. aureus*, respectively.¹⁸ Thus, susceptibility to moxifloxacin was only 50% to 60%²⁷ or 76% (Rosenberg KD et al. *IOVS* 2004;45:ARVO E-Abstract 509) for fluoroquinolone-resistant coagulase negative *Staphylococcus* isolated from patients with endophthalmitis. Oral moxifloxacin cannot achieve sufficient intravitreal and intracameral levels for fluoroquinolone-resistant *Staphylococcus*. Intravitreal injection of 400 µg moxifloxacin in the human eye, which results in an intravitreal concentration of 100 µg/mL, would be sufficient to cover all fluoroquinolone-resistant staphylococci.

Thus, if proven safe and efficacious by further study in humans, intravitreal injection of moxifloxacin could be considered an alternative to currently used antibiotics in selected patients with resistant bacterial infection or allergy to the more traditional antibiotics.

References

- Han DP, Wisniewski SR, Wilson LA, et al. Spectrum and susceptibilities of microbiologic isolates in the Endophthalmitis Vitrectomy Study. *Am J Ophthalmol*. 1996;122:1-17.
- Endophthalmitis Vitrectomy Study Group. Results of the Endophthalmitis Vitrectomy Study: a randomized trial of immediate vitrectomy and of intravenous antibiotics for the treatment of postoperative bacterial endophthalmitis. *Arch Ophthalmol*. 1995;113:1479-1496.
- Campochiaro PA, Conway BP. Aminoglycoside toxicity: a survey of retinal specialists—implications for ocular use. *Arch Ophthalmol*. 1991;109:946-950.
- Diamond JP, White L, Leeming JP, et al. Topical 0.3% ciprofloxacin, norfloxacin, and ofloxacin in treatment of bacterial keratitis: a new method for comparative evaluation of ocular drug penetration. *Br J Ophthalmol*. 1995;79:606-609.
- Bower KS, Kowalski RP, Gordon YJ. Fluoroquinolones in the treatment of bacterial keratitis. *Am J Ophthalmol*. 1996;121:712-715.
- Donnenfeld ED, Schrier A, Perry HD, et al. Penetration of topically applied ciprofloxacin, norfloxacin, and ofloxacin into the aqueous humor. *Ophthalmology*. 1994;101:902-905.
- Rowen S. Preoperative and postoperative medications used for cataract surgery. *Curr Opin Ophthalmol*. 1999;10:29-35.
- Goldstein MH, Kowalski RP, Gordon YJ. Emerging fluoroquinolone resistance in bacterial keratitis: a 5-year review. *Ophthalmology*. 1999;106:1313-1318.
- Goldstein EJ, Garabedian-Ruffalo SM. Widespread use of fluoroquinolones versus emerging resistance in pneumococci. *Clin Infect Dis*. 2002;35:1505-1511.
- Kowalski RP, Karenchak LM, Romanowski EG. Infectious disease: changing antibiotic susceptibility. *Ophthalmol Clin North Am*. 2003;16:1-9.
- Nightingale CH. Moxifloxacin, a new antibiotic designed to treat community-acquired respiratory tract infections: a review of microbiologic and pharmacokinetic-pharmacodynamic characteristics. *Pharmacotherapy*. 2000;20:245-256.
- Dalhoff A, Krasemann C, Wegener S, et al. Penicillin-resistant streptococcus pneumoniae: review of moxifloxacin activity. *Clin Infect Dis*. 2001;32(suppl 1):S22-S29.
- Talan DA. Clinical perspectives on new antimicrobials: focus on fluoroquinolones. *Clin Infect Dis*. 2001;32(suppl 1):S64-S71.
- Rossi C, Sternon J. Fluoroquinolones of the third and fourth generations (in French). *J Pharm Belg*. 2001;56:137-148.

15. Schedletzky H, Wiedemann B, Heisig P. The effect of moxifloxacin on its target topoisomerases from *Escherichia coli* and *Staphylococcus aureus*. *J Antimicrob Chemother*. 1999;43(suppl B):31-37.
16. Pestova E, Millichap JJ, Noskin GA, et al. Intracellular targets of moxifloxacin: a comparison with other fluoroquinolones. *J Antimicrob Chemother*. 2000;45:583-590.
17. Blondeau JM, Laskowski R, Bjarnason J, et al. Comparative in vitro activity of gatifloxacin, grepafloxacin, levofloxacin, moxifloxacin and trovafloxacin against 4151 Gram-negative and Gram-positive organisms. *Int J Antimicrob Agents*. 2000;14:45-50.
18. Kowalski RP, Dhaliwal DK, Karenchak LM, et al. Gatifloxacin and moxifloxacin: an in vitro susceptibility comparison to levofloxacin, ciprofloxacin, and ofloxacin using bacterial keratitis isolates. *Am J Ophthalmol*. 2003;136:500-505.
19. Saszik SM, Robson JG, Frishman IJ. The scotopic threshold response of the dark-adapted electroretinogram of the mouse. *J Physiol*. 2002;543:899-916.
20. Mordenti J, Thomsen K, Licko V, et al. Intraocular pharmacokinetics and safety of a humanized monoclonal antibody in rabbits after intravitreal administration of a solution or a PLGA microsphere formulation. *Toxicol Sci*. 1999;52:101-106.
21. Lyubarsky AL, Pugh EN, Jr. Recovery phase of the murine rod photoreponse reconstructed from electroretinographic recordings. *J Neurosci*. 1996;16:563-571.
22. Howes KA, Pennesi ME, Sokal I, et al. GCAP1 rescues rod photoreceptor response in GCAP1/GCAP2 knockout mice. *EMBO J*. 2002;21:1545-1554.
23. Pugh EN Jr, Falsini B, Lyubarsky AL. The origin of the major rod- and cone driven components of the rodent electroretinogram, and the effect of age and light-rearing history on the magnitudes of these components. In: Williams TP, Thistle AB, eds. *Photostasis and Related Topics*. New York: Plenum; 1998.
24. Hariprasad SM, Blinder KJ, Shah GK, et al. Penetration pharmacokinetics of topically administered 0.5% moxifloxacin ophthalmic solution in human aqueous and vitreous. *Arch Ophthalmol*. 2005;123:39-44.
25. Hariprasad SM, Shah GK, Mieler WF, et al. Vitreous and aqueous penetration of orally administered moxifloxacin in humans. *Arch Ophthalmol*. In press.
26. Jones RN, Biedenbach DJ. Comparative activity of garenoxacin (BMS 284756), a novel desfluoroquinolone, tested against 8,331 isolates from community-acquired respiratory tract infections: North American results from the SENTRY Antimicrobial Surveillance Program (1999-2001). *Diagn Microbiol Infect Dis*. 2003;45:273-278.
27. Mather R, Karenchak LM, Romanowski EG, et al. Fourth generation fluoroquinolones: new weapons in the arsenal of ophthalmic antibiotics. *Am J Ophthalmol*. 2002;133:463-466.